



International Journal of Molecular and Clinical Microbiology



Pneumonia caused by *Mannheimia haemolytica* in goats at a slaughterhouse in Rasht, Iran

Majid Shokri¹, Ebrahim Pourmirbolouk Jalali², Elham Houshmand², Afshin Zahedi², Ershiya Bagheri Torbehbar³

1. MS in Vet Bacteriology, Department of Pathobiology, Faculty of Veterinary Medicine, Rasht Branch, Islamic Azad University, Gilan, Iran

2. Department of Pathobiology, Faculty of Veterinary Medicine, Rasht Branch, Islamic Azad University, Gilan, Iran

3. B.S.c. in Biology, Department of Biology, Faculty of Basic Science, Rasht Branch, Islamic Azad University, Gilan, Iran

ARTICLE INFO

Article history:

Received 5 March 2019

Accepted 27 April 2019

Available online 1 June 2019

Keywords:

Mannheimia, *Pneumonia*, *goat*,
Rasht, *Iran*

ABSTRACT

Bronchopneumonia caused by *Mannheimia haemolytica* and *Pasteurella multocida*, in sheep and goats often occurs in livestock that are under stresses such as transportation, milk catching, changing diets, or being with other animals from other farms. In this study, from June to November 2018, 230 goats at a slaughterhouse in Rasht were examined for pulmonary lesions. Of the total 230 samples, 82 cases (35.6%) had one or more macroscopic lesions. *Mannheimia haemolytica*, *Pasteurella multocida* and *Bibersteinia trehalosi* were detected in 0.9%, 0.45% and 0.45% of positive samples, respectively. In two cases (0.9%), bronchiectasis was observed in the lower anterior region. In the microscopic view of the tissue sections, with the exception of one case that had typical symptoms of acute interstitial pneumonia and oxidative phase observed, 81 other cases (35.2%) showed typical symptoms of enzootic pneumonia and, in one case, focal necroses were observed. The inflammation of the pleura was not seen in goats less 6 months of age, but was observed in 44% of samples 6-12 months and 95% of samples more than 12 months. Based on this study that was conducted for the first time in the north of Iran, enzootic pneumonia and inflammation of the pleura are the most important problems of goats over one year and *Mannheimia haemolytica* can be one of the potential causes of pneumonia.

1. Introduction

Bronchopneumonia, caused by *Mannheimia haemolytica* and *Pasteurella multocida*, infects sheep and goats of all ages and often occurs in livestock that are under stresses such as transportation, milk catching, changing diets, or being with other animals from other farms. *Bibersteinia trehalosi* can also cause septicemia or systemic pasteurellosis at the age of 4 to 9 months (Aiello and Moses, 2016). *Mannheimia haemolytica* and *Bibersteinia trehalosi* are the

main factors of pasteurellosis in sheep and goats. According to the old classification, *Mannheimia haemolytica* was divided into two biotypes A and T, which were later divided into different serotypes based on the antigenic differences in the polysaccharide capsule. The serotypes existing in biotype A are now called *Mannheimia haemolytica*, with the exception of the A11 serotype, a distinct species called *Mannheimia glycoside*. The most common

*Corresponding author: Dr. Elham Houshmand
Phone: +989111834813
E-mail: drehooshmand@iaurasht.ac.ir

symptom of infection by *Mannheimia haemolytica* in sheep is Pasteurellosis pneumonia that occurs in all ages. This bacteria is a secondary attacker and causes death from chronic enzootic pneumonia in sheep and goats which started by mycoplasma (Constable et al. 2017). There are only a few reports of the Pasteurellosis due to *Mannheimia* from Iran. In 2009, when a study was conducted on sheep's lungs in Garmsar, *Mannheimia* was not detected, but *Pasteurella trehalosei* was reported (Ghadrdan Mashhadi et al. 2009). In a study in Tehran, *Pasteurella multocida* and *Mannheimia haemolytica* were introduced as the main cause of disease in calves with respiratory disease (Fakour and Norouzian, 2017). Also in 2018, with molecular and culture techniques, *Mannheimia haemolytica* was isolated from the lungs of sheep with pneumonia in Shiraz (Tabatabaei and Abdollahi, 2018). The aim of this study was to investigate the prevalence of this bacterium in the slaughtered goats in Rasht, which is being conducted for the first time in the north of Iran.

2. Materials and Methods

In this study, which was carried out in slaughterhouse of Rasht, from June to November 2018, 230 goats were examined for pulmonary lesions. Of these, 82 cases of lungs with macroscopic pneumonia were detected and seized. Then under sterile conditions, sampling, culturing and biochemical tests were performed and finally, isolates were identified according to Brogden et al., 1998. During the work, care was taken that the sterilized swab did not enter bronchial tubes, since *Pasteurella* is a natural flora in these organs.

For pathologic study, three to five tissue samples with 1cm in diameter from each lung, including healthy and damaged tissue, were placed in 10% formalin to be used in the preparation of histopathological sections. The preparation of tissue sections was done by paraffin technique and the sections fixed on the slide were stained with Hematoxylin and Eosin technique and studied under an optical microscope.

3. Results

In the macroscopic view, all the damaged lungs were bulky and larger than normal. The marks of the ribs were seen on some lungs. Almost all lungs exhibited different degrees of hepatization in the lower anterior part, with varying degrees of thickening the space between lobules. In two cases (4/2%), bronchiectasis was observed in the lower anterior region. On the cross-section, the lungs usually show signs of Hyperemia. In none of the cases, neoplasia, granulomatous inflammation, purulent exudate, or parasites were observed. *Mannheimia haemolytica*, *Pasteurella multocida* and *Bibersteinia trehalosi* were detected in 0.9%, 0.45% and 0.45% of positive samples, respectively.

In the microscopic view of the tissue sections, with the exception of one case, typical symptoms of acute interstitial pneumonia with oxidative phase observed, 81 other cases (35.2% of all cases and 98.8% of cases with symptoms) showed typical symptoms of enzootic pneumonia, in which the walls between alveoli was thickened due to edema, hyperemia and inflammatory cells infiltration, lymphofollicular aggregates around the bronchi and bronchioles, small blood vessels and capillaries (cuffing pneumonia), type I pneumocytes necrosis and their replacement by ^{hyper}plastic pneumocytes type II (epithelialization/fetalization), and in one case, focal necrosis were observed with oat macrophages/swirling macrophages. The inflammation of the pleura along with its thickening and infiltration of inflammatory cells was also evident from other microscopic changes observed in many specimens.

In the microscopic studies of the apparently healthy lung tissue sections, except few cases of blood aspiration and some partial hyperemia cases, no other pathologic changes were observed. In the present study, the assortment pattern of slaughtered goats with pneumonia lesions differing in age; 12.2% were less than 6 months, 61% between 6 to 12 months and 26.8% more than 12 months. The inflammation of the pleura was also studied that it was not seen in goats less 6 months of age, but was observed in 44% of samples 6-12 months and 95% of samples more than 12 months.

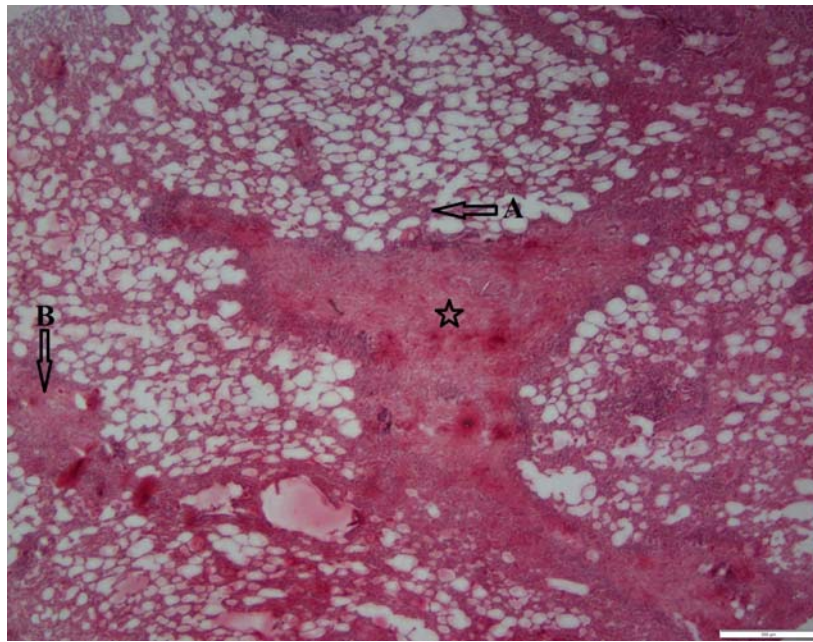


Figure 1. The tissue section of goat's lung. The Interstitial pneumonia: thickening of the alveolar space (black arrow), infiltration and accumulation of cells inflammation in the wall between alveolar and around blood vessels and bronchioles (yellow arrow) and area of necrosis (star) are visible. Magnification x 40, Hematoxylin and Eosin staining.

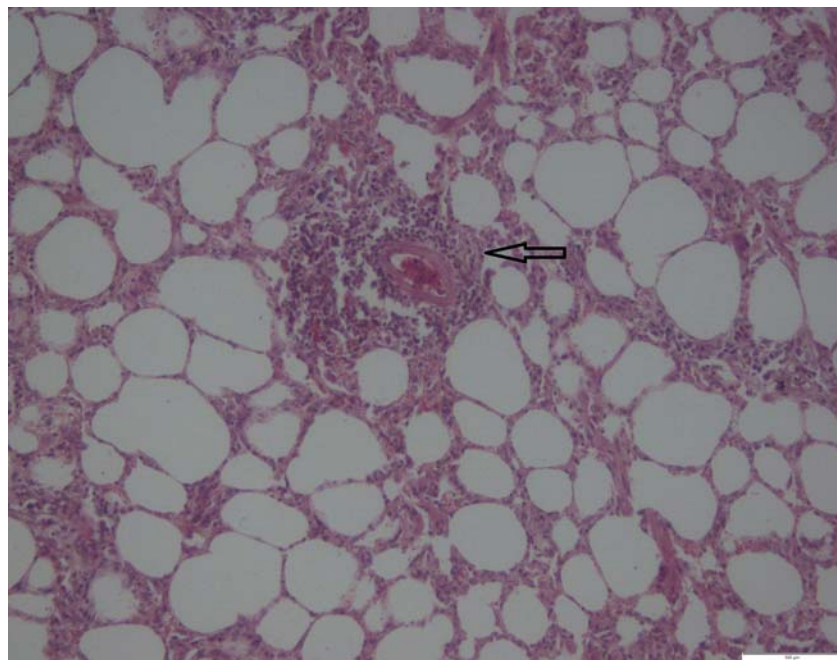


Figure 2. The accumulation of lymphatic cells around the blood vessels (cuffing pneumonia, arrow), thickening of the alveolar wall due to inflammatory cell infiltration. Magnification x 100, Hematoxylin and Eosin stain.

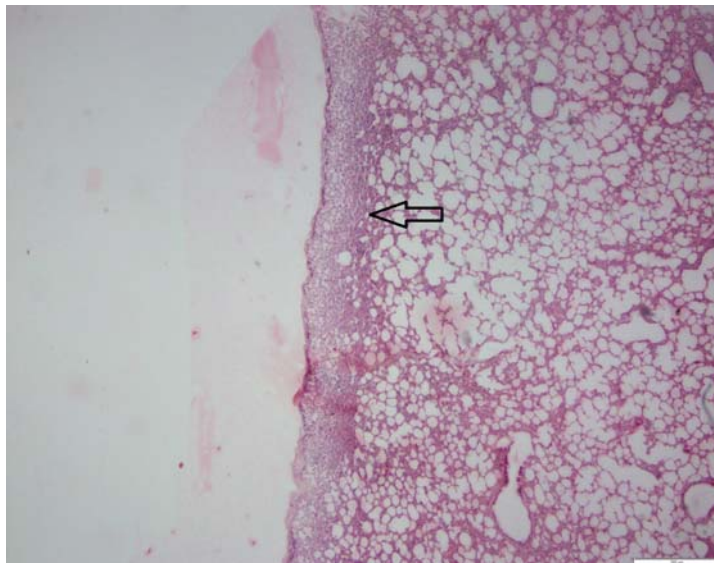


Figure 3. pleura. Thickening of the pleura due to the inflammatory cell inflammation, fibrin and edema (arrow). Magnification x 40. Hematoxylin and Eosin staining.

4. Discussion

Pneumonia in ruminants is a complex condition that is the result of host defense ability (namely, physiological and immunological factors), etiologic factors (such as bacterial, viral, and mycoplasma), and environmental factors. Pneumonia occurs in all ages of sheep and goats, and in every country of world. Factors such as crowding, dust, water and damp humid weather and stress conditions like high fatigue, hunger, cold, cut off horn or dehorn can increase the disease (Tabatabaei and Abdollahi, 2018). One of these factors is pneumonia caused by *Mannheimia haemolytica*.

Mannheimia haemolytica is a gram negative coccobacillus, non-motile, non-spore forming which is known as an opportunistic pathogen and the main factor of pneumonic pasteurellosis, as well as found as a natural flora on the mucous membrane of the respiratory tract of goats (Tabatabaei and Abdollahi, 2018). Apart from pulmonary infections, *Mannheimia haemolytica* is associated with systemic infection in ruminants (Abinet et al. 2018). In sheep, the illness caused by *Mannheimia* is more likely to include pneumonia and septicemia (Louise et al. 2006). Respiratory tract infection is seen in all native and domestic species. Pasteurellosis pneumonia is also known as respiratory mannheimiosis, which is the most common example with a wide prevalence in ruminant

animals. In goats, clinical symptoms include fever, loss of appetite, wheezing, nasal discharge, and breathing with open mouth. Pneumonia in sheep and goats, initially caused by mycoplasma, reach the highest point of complexity by *Mannheimia*. The disease, in its typical clinical form, is highly infectious, often fatal and with very serious economic impact in animal industry. In North America, more than one billion dollars are lost in beef cattle industry. Delay in sales of livestock, losses caused by disease, low value of carcasses and slaughter house waste are among the other disadvantages of pneumonia caused by *Mannheimia haemolytica* (Mohamed. and Andelsalam, et al. 2008)

In 2002, an investigation into an outbreak of acute respiratory disease involved 4 flocks (722 sheep and 750 goats in total) was conducted in Ethiopia. *Mannheimia haemolytica* was isolated from nine (six goats and three sheep) out of 23 nasal swabs (39.1%). Livestock with severe respiratory distress revealed pulmonary lesions of necrotic fibrinous pneumonia and blood fluid accumulation under pleura, also in culturing samples harvested from lung lesions and accumulated fluid in the chest cavity, *Mycoplasma capricolum*, *Pseudomonas aeruginosa*, and an unknown species of *Mycoplasma* were isolated (Shiferaw et al. 2006).

During 2006 and 2007, a biochemical and molecular study on 196 swab samples was taken from nose and throat mucosal secretions of sheep and goats in Jordan, and 14 cases (7.14%) of *Pasteurella multocida* and two cases (1.02%) of *Mannheimia haemolytica* were isolated (Hawari et al. 2008).

In 2009, in an investigation prevalence of pneumonia in slaughtered goats, 91.4% was determined in Turkey, in which 2.43% were parasitic pneumonia. The rest of the cases were investigated by immunohistochemical method to detect *Mannheimia haemolytica* antigen and in total this antigen was detected in 45% of the cases of non-parasitic pneumonia (Yener et al. 2009).

In 2008 to 2010, in research using molecular and culture techniques in sheep with epizootic pneumonia was conducted in western America. *Pasteurella multocida*, *Mannheimia haemolytica*, *Bibersteinia trehalosi* and *Mycoplasma pneumonia* were isolated and due to the presence of mycoplasma pneumonia in 95% of infected flocks and its absence in uninfected flocks, this bacterium was introduced as the main cause of the disease (Besser et al. 2012).

In 2003 to 2012, in a 10-year survey in India, 224 goats' lung cases were affected by pneumonia, *Acholeplasma* with 8.19% and *Mycoplasma arginine* with 5.3% had the highest rate of pneumonia (Valsala et al. 2017).

In 2019, with the sampling of lung and blood in 14 goats who died from pneumonia and exhibited by necropsy bronchopneumonia of acute fibrinous necrosis, were identified in five cases of *Pasteurella multocida* and seven cases of *Mannheimia haemolytica*. However, two carcasses showed simultaneous contamination to both bacteria (Rawat et al. 2019).

In Iran, the prevalence of pneumonia and other pulmonary disorders is foreseen approximately 10%. The prevalence of pneumonia by *Mannheimia* is geographically different and depends on climate changes and racial resistance of livestock in the region.

In a study conducted in Garmsar, district of Iran in 2009, 120 cases of slaughtered sheep (60 healthy sheep and 60 sheep with pneumonia) were examined. In none of them, *Mannheimia haemolytica* was observed, while in 15% of healthy lungs and 90% of lungs with lesions, other bacteria such as *Pseudomonas*, *Proteus*,

Arcanobacterium pyogenes, *Klebsiella*, *Enterobacter*, *Streptococcus*, *Escherichia coli* and *Pasteurella trehalosi* were reported (Ghadrdan Mashhadi et al. 2009)

Facour and Norouzian in 2017, by microbial culture and biochemical reactions of nasal drainage in calves with respiratory diseases, introduced *Pasteurella multocida* and *Mannheimia haemolytica*, as the main causes of disease.

In 2018, Tabatabaei and Abdollahi, by molecular techniques and culture in 38 out of 161 lung samples with pneumonia lesions (23.6%) which were collected from Shiraz slaughterhouse, had isolated *Mannheimia haemolytica*.

In this study which was conducted on 230 goat samples in Rasht slaughter house, 82 lung cases had macroscopic lesions and of these, two cases were infected by *Mannheimia haemolytica*, one case infected by *Pasteurella multocida* and one case infected by *Bibersteinia trehalosi*. Inflammation of the pleura was not seen in the samples of less than 6 months goats, while 95% samples of goats aged more than one year were found to have inflammation of the pleura.

In Iran, there are few studies on the agents causing pneumonia in goats. However, except in Garmsar study in which *Mannheimia* was not isolated, the prevalence rate of *Mannheimia* in Rasht (this study) is lower than other areas of Iran.

It is clear that one of the problems today that has brought much financial burden to the livestock industry is infectious pulmonary disease. Pneumonia, which has prevalence in all countries, displays the annual highest rate of mortality. Based on the results of this study that was conducted for the first time in the north of Iran, inflammation of the pleura is the most important problem of goats over one year and it seems that enzootic pneumonia plays a major role in the occurrence of pneumonia and the number one factor in lung removal of slaughtered goats in Rasht.

One of the factors that can lead to complications is *Mannheimia haemolytica*, which naturally occurs in tonsils, nose and throat, and stress combined with viral or bacterial agent can lead to weakening of pulmonary immune system, and afterwards this barrier allows *Mannheimia haemolytica*

to enter the respiratory system and eventually damage the lung tissues (Brogden et al. 1998). On the other hand, traditional therapies based on the high consumption of antibiotics, which include synthetic drugs, have ultimately led to multiple drug resistance in *Mannheimia haemolytica* (Abinet et al. 2018). Based on this study, however the presence of this bacterium in the examined samples was low, but it can be one of the potential causes of pneumonia and the presence of bacteria in stressful conditions can lead to severe disease and death.

Refereces

- Aiello, S.E., Moses, M.A. (2016). The Merck Veterinary Manual, 11th Edition, Wiley. ISBN: 978-0-911-91061-2.
- Besser, T.E., Highland, M.A., Baker, K., et al. (2012). Causes of Pneumonia Epizootics among Bighorn Sheep, Western United States, 2008–2010. *Emerg Infect Dis*, 18(3): 406-414.
- Brogden, K.A., Lehmkuhl, H.D., Cutlip, R.C. (1998). *Pasteurella haemolytica* complicated respiratory infections in sheep and goats. 29(3-4): 54-233.
- Constable, P.D., Hinchcliff, K.W., Done, S.H., Grünberg, W. (2017). Systemic and Multi-Organ Diseases. In *Veterinary Medicine*, 11th Edition, Saunders Ltd. ISBN 978-0-7020-5246-0, P: 2002-2214.
- Fakour, S., Norouzian, I. (2017). Bacteriological and therapeutic studies on *Mannheimia haemolytica* and *Pasteurella multocida* in bovine respiratory disease at dairy cattle farms in Tehran. *Razi Vaccine & Serum Research Institute*. 72(1): 9-14.
- Ghadrdan Mashhadi, A.R., Asgari Badouei, M., Safari Dastjerdehei, H., Ashrafi tamay, I. (2009). A survey on role of *Mannheimia haemolytica* in Sheep Pneumonia in Garmsar. *Journal of Islamic.Azad.University, Garmsar Branch*, 5(2):105-108 (in Persian).
- Hawari, A.D., Hssawi, D.S., Sweiss, M. (2008). Isolation and Identification of *Mannheimia haemolytica* and *Pasteurella multocida* in Sheep and Goats using Biochemical Tests and Random Amplified Polymorphic DNA (RAPD) Analysis. *Journal of biological science*. 8(7): 1251-1254.
- Legesse, A., Abayneh, T., Mamo, G., et al. (2018). Molecular characterization of *Mannheimia haemolytica* isolates associated with pneumonic cases of sheep in selected areas of Central Ethiopia. *BMC microbiology*. 19(23): 1-55.
- Mohamed, R.A., Abdelsalam, E.B. (2008). A review on pneumonic pasteurellosis (respiratory mannheimiosis) with emphasis on pathogenesis, virulence mechanisms and predisposing factors. *Bulgarian Journal of Veterinary Medicine*. 11(3): 139-160.
- Poulsen, L.L., Reinert, T.M., Sand, R.L., et al. (2006). Occurrence of haemolytic *Mannheimia* spp. in apparently healthy sheep in Norway. *Acta Veterinaria Scandinavica*. 20(49): 1-13.
- Rawat, N., Gilhare, V.R., Kushwaha, K.K., et al. (2019). Isolation and molecular characterization of *Mannheimia haemolytica* and *Pasteurella multocida* associated with pneumonia of goats in Chhattisgarh, *Veterinary World*. 12(2): 331-336.
- Shiferaw, G., Tariku, S., Ayelet, G., Abebe, Z. (2006). Contagious caprine pleuropneumonia and *Mannheimia haemolytica*-associated acute respiratory disease of goats and sheep in Afar Region, Ethiopia. *Rev. sci. tech. Off. int. Epiz*, 25(3): 1153-1163.
- Tabatabaei, M., Abdollahi, A.F. (2018). Isolation and identification of *Mannheimia haemolytica* by culture and polymerase chain reaction from sheep's pulmonary samples in Shiraz, Iran. *Vet World*. 11(5):636-641.
- Valsala, R., Rana, R., Remesh, A.T., Singh, V.P. (2017). *Mycoplasma arginini*: high frequency involvement in goat pneumonia. *Turk J Vet Anim Sci*. 41: 393-399.
- Yener, Z., Ilhan, F., Saglam, Y.S. (2009). Immunohistochemical detection of *Mannheimia (Pasteurella) haemolytica* antigens in goats with natural pneumonia. *Vet Res Commun*. 33(4): 305-13.